

Ridge Preservation and Augmentation Using Regenerative Materials to Enhance Implant Predictability and Esthetics

Abstract

Dentistry has entered an era in which patients no longer need to accept an edentulous or partially edentulous condition, or one in which their candidacy for tooth structure replacement (ie, implants with subsequent restoration) must be dismissed because of insufficient alveolar bone volume, height, or width. The supporting bone can be preserved at the time of tooth extraction, or augmented at the time of case presentation, using a variety of available regenerative materials. Among them are mineralized human allograft bone and collagen membranes that can be placed in combination with specific growth factor complexes and implant designs. This article reviews the challenges associated with adequately preserving or augmenting the alveolar bone after tooth extraction or loss and before implant placement. The research and benefits to support using allogenic bone graft and membrane materials for such procedures are detailed, and 3 clinical cases are presented to demonstrate the clinically successful incorporation of these materials with the host tissues.

Learning Objectives

After reading this article, the reader should be able to:

- explain why preservation and augmentation of the alveolar bone at the time of tooth extraction is significant to subsequent implant placement and restoration processes.
- discuss some of the bone graft materials and techniques in use today to facilitate bone preservation and augmentation.
- describe the clinical and patient benefits of using allograft materials for bone preservation and augmentation before implant placement.
- explain the manner in which bone graft, barrier membranes, biologic modifiers, and other state-of-the-art technologies can be used in conjunction with one another to facilitate predictable treatment outcomes.

When dental treatment involves restoration of an extracted tooth, one that is missing because of trauma, or one missing congenitally, preservation and/or augmentation of the alveolar ridge dimensions is of paramount importance.¹ The bone volume in the maxillary and mandibular alveolar ridges in buccolingual and apicocoronal directions influences a variety of factors related to oral health and potential restorative treatment, including the

location and position of implants when placed, their subsequent success or failure, and the esthetics of the definitive restorations.^{2,3} Long-term esthetic success requires vital alveolar bone to support healthy keratinized tissue and dictate the soft-tissue profile, which follows the underlying bone contour.^{2,3}

Alveolar bone loss can occur after tooth extraction and/or trauma. Atrophy of the alveolar bone also may occur in areas of congenitally missing teeth, and adverse alveolar bone conditions

J. Daulton Keith, Jr., DDS, FICD
Private Practice
Charleston, South Carolina

Maurice A. Salama, DMD
Private Practice
Atlanta, Georgia

Sponsored by an educational grant from Zimmer Dental

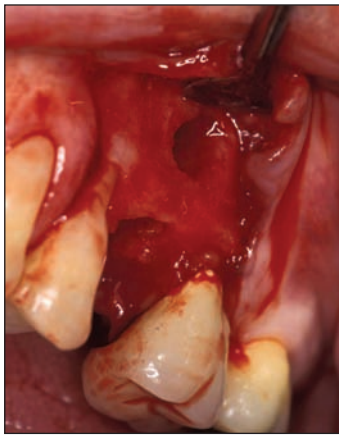

Figure 1A—Extraction of tooth No. 13 resulted in a large apical defect at the site, in addition to complete destruction of the labial plate.

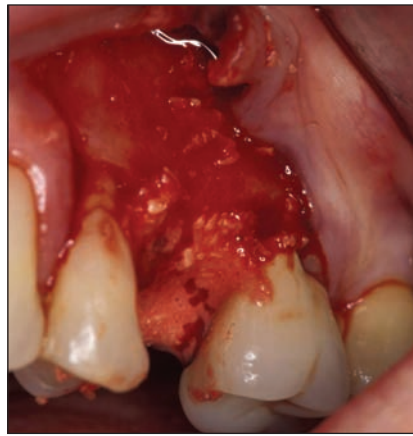

Figure 1B—A mineralized particulate bone was placed in the defect.

also can result from advanced periodontal disease and failed endodontic therapy.⁴ When the resorptive patterns of the alveolar bone progress horizontally and vertically, a more lingually positioned ridge can result.² It has been suggested that if the alveolar ridge is not preserved at the time of tooth extraction or tooth loss, alveolar ridge height and width—as well as position—may be lost, particularly in the area of the buccal (ie, facial) plate.^{5,6} Major changes have been demonstrated to occur in extraction sites during the first year after tooth extraction,⁷ and losses of between 3 mm and 6 mm horizontally and 1 mm and 2 mm vertically have been reported.^{3,5,7-9}

Preserving the alveolar ridges at the time of tooth extraction helps to minimize difficulties during subsequent implant placement.² A site planned for implant placement requires sufficient bone height and width to ensure stability and ideal soft-tissue contours.³ The minimum amount of bone recommended on the buccal or lingual aspects is 1 mm, with at least 2 mm of facial bone required for implants in the esthetic zone.^{3,10}

The most predictable way to maintain the width, height, and position of the alveolar ridges is preservation at the time of tooth extraction.^{2,5,6} When there is insufficient existing bone volume (eg, resulting from atrophy and congenitally missing dentition), the ridge can be augmented using appropriate surgical techniques, including guided bone regeneration with barrier membranes, bone grafts, and biologic modifiers.¹¹⁻¹³ The materials and surgical techniques in use today facilitate bone preservation and augmentation before implant placement and enable clinicians to more predictably ensure the functional and esthetic outcomes of the implants and subsequent restorations that are delivered.¹⁻³

Bone grafting can be completed using a variety of materials, such as autografts (ie, the patient's own bone, which requires multiple and potentially painful procedures), allografts (ie, human bone, not from the patient), and xenografts (ie, animal bone) or alloplasts (ie, synthetic bone).^{1,3} Autografts are osteogenic and contain bone-forming cells; allografts can be osteoconductive and osteoinductive, attracting cells that are bone-forming; and xenografts and alloplasts are osteoconductive, acting as “scaffolds” for

other cells that are bone-forming.³ Allografts may be demineralized or mineralized freeze-dried bone allograft materials. Mineralized bone allografts preserve the calcium and phosphate salts and, therefore, resorb slower than demineralized freeze-dried bone allografts.^{1,3}

One human mineralized cancellous particulate bone allograft (Puros^a) is slowly resorbed and replaced with the patient's natural bone.¹³ This is because the material preserves the natural collagen matrix, trabecular pattern, and porosity of human cancellous bone. Histological analysis following placement after tooth extraction demonstrates the efficacy of this material.^{14,15}

The most predictable way to maintain the width, height, and position of the alveolar ridges is preservation at the time of tooth extraction.

When properly prepared and delivered according to a standardized surgical technique that has been evaluated in the literature,¹⁶ a novel, sterilized, antigen-inactivated mineralized block allograft (Puros Block Allograft^a) demonstrates a high degree of predictability. Technique requisites include proper contouring and shaping to fit the defect site, screw fixation to prevent block allograft rotation, contouring of the block allograft to prevent soft-tissue complications, and coverage of the graft site with a barrier membrane that may or may not have been saturated in platelet-rich plasma.¹⁶ Additionally, soft-tissue closure must be accomplished without tension.¹⁶

When placed in atrophic human maxillae, this mineralized bone allograft has been shown to form new bone, and all subsequently placed Tapered Screw-Vent implants^a achieved osseointegration.^{4,15} What's more, research also determined that resorption and replacement by new bone occurred more rapidly with the regenerative, mineralized bone allograft that was tested.¹⁵

In one report of 4 cases, it was found that the allogenic bone block that was used (Puros J-Block^a) was an effective

^a Zimmer Dental, Carlsbad, CA; www.zimmerdental.com

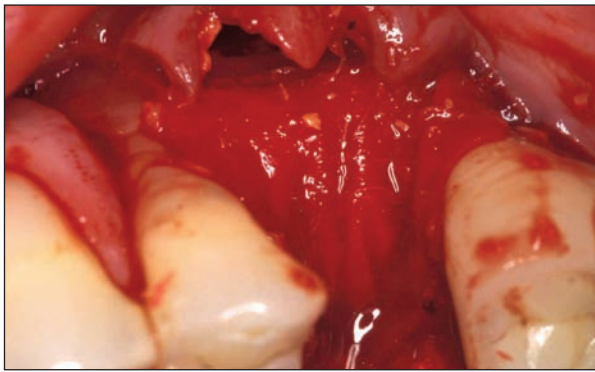


Figure 1C—The bone block graft was covered using a regenerative collagen matrix membrane.

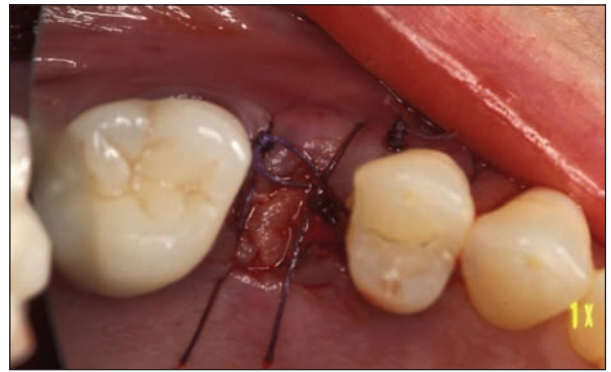

Figure 1D—At 2 weeks postoperative, the absorbable membrane remained intact.

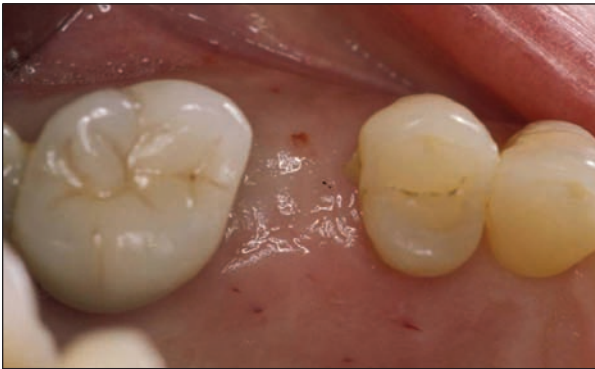

Figure 1E—Three-month postoperative view revealing excellent and adequate areas of keratinized tissue that were created with the use of the regenerative membrane.

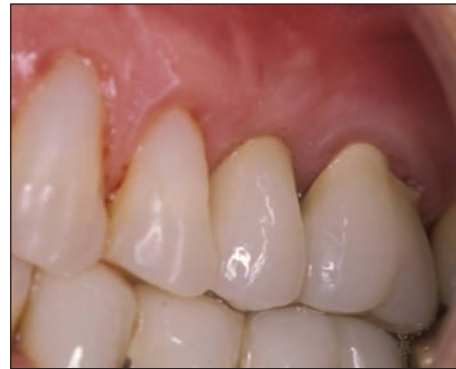

Figure 1F—Two-year postoperative view of the implant-supported restoration at tooth No. 13. Note esthetic ridge and soft-tissue contours.

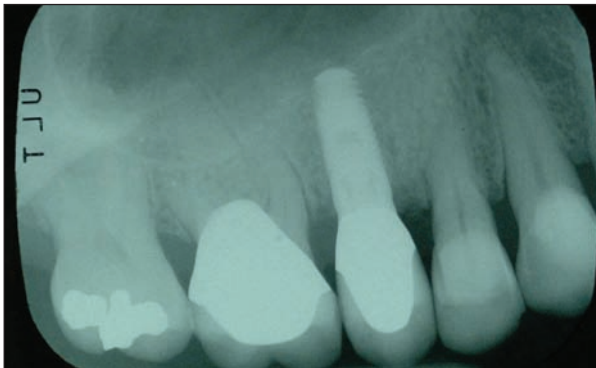

Figure 1G—Two-year postoperative radiograph demonstrating osseointegration of the implant with the regenerated bone and excellent ridge contours.

alternative to harvesting and grafting autogenous bone for implant site development—one that clinically generates new bone fill for implant placement.¹⁷ Using mineralized, cortico-cancellous bone allograft can eliminate the additional surgical procedure necessary for harvesting an autograft; however, it requires precise shaping and contouring to adapt the allograft to the defect site.¹⁸ This aspect of the technique sensitivity associated with the preparation and placement of block allografts may be mitigated using state-of-the-art imaging and modeling technology.¹⁸⁻²⁰

Specifically, data from computed tomography (CT) scans can be used to fabricate accurate 3-D stereolithic

models of a patient's jaw that can be presurgically fitted with the planned allograft and sterilized for later transfer to the mouth for use as a template.¹⁸⁻²⁰ Using 3-D CT imaging, the clinician can critique the allograft from different perspectives, without such intraoral challenges as bleeding, flaps, and restricted access.¹⁸ As a result, an additional advantage is the reduced risk of complications or failure from poorly contoured allografts.¹⁸⁻²⁰ Further, the time required for the grafting procedure can be reduced by eliminating the need to prepare the block allograft at the time of the surgical appointment.¹⁸

When implants ultimately are to be placed, clinicians can insert them with confidence that they will function successfully long-term in ridges that have been preserved and/or augmented with regenerative materials. One investigation showed that bone regenerated using a membrane technique reacts to implant placement like nonregenerated bone, achieving successful tissue integration with functional ankylosis.²¹ In a later study that analyzed 526 implants placed and loaded in regenerated bone, the researchers found that the regenerated bone reacted to implant placement in a clinically similar manner as native bone.²²

The barrier membranes mentioned earlier may be resorbable (eg, collagen), nonabsorbable (eg, expanded polytetrafluoroethylene), or acellular dermal matrices that serve as barriers and can be used when the buccal wall is deficient to protect the bone graft after placement.¹³

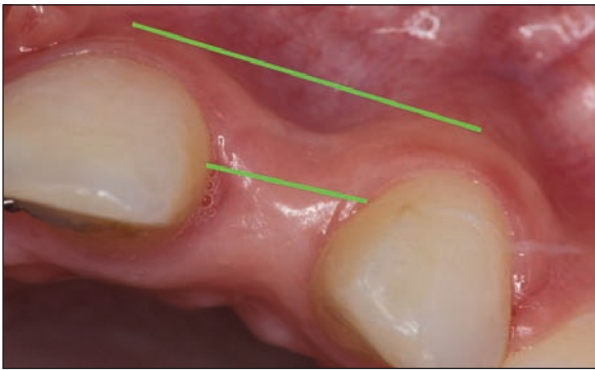


Figure 2A—The patient presented with extreme atrophy of the alveolar bone at the area of tooth No. 10, which was congenitally missing.

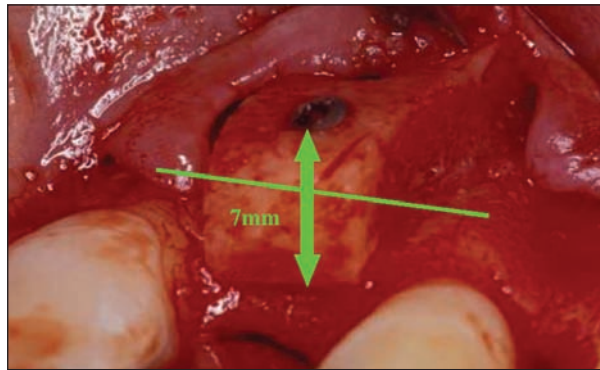


Figure 2B—The allograft bone block was placed and, upon examination, demonstrated the desired cortical/trabecular patterns necessary for dimensional ridge augmentation.

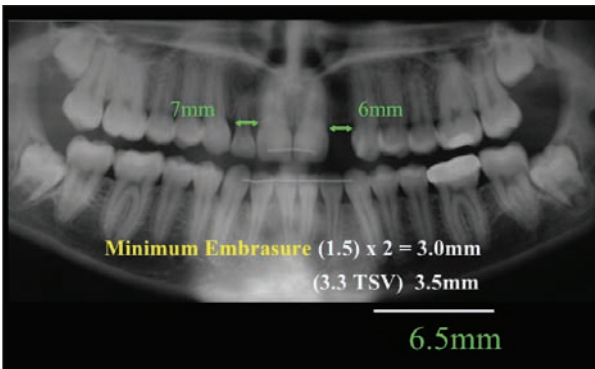


Figure 2C—The preoperative panoramic radiograph identifies the root positions of teeth Nos. 9 and 11, as well as their mesiodistal spatial relationship. This was compared to the contralateral maxillary right lateral incisor for reference.

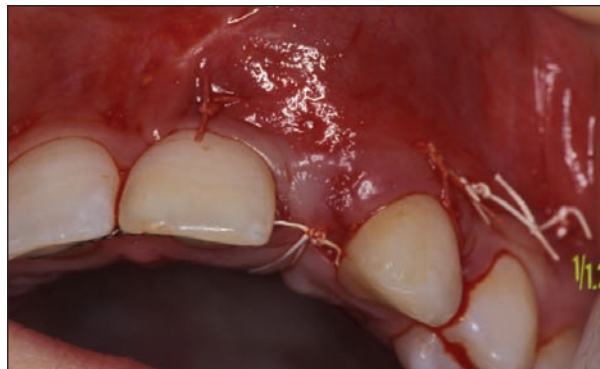


Figure 2D—Postoperative view with the allograft bone block in place, protected/covered by a regenerative membrane.

Biologic modifiers include preparations rich in growth factors harvested from the patient's own blood. They are used to form a fibrin matrix that can further protect the graft and induce cell proliferation.^{24,25}

All of these materials or some combination thereof have demonstrated clinical efficacy for site preservation, augmentation, and implant integration at the affected site.^{4,15,17,26} The 3 cases described here highlight the use of specific regenerative materials and techniques to preserve the alveolar ridge after tooth extraction and/or augment the bone to accommodate anticipated implant and restorative requirements.

Case No. 1 (Dr. Keith): Single-Tooth Extraction Site Precipitated By Endodontic Failure

A 63-year-old woman, a nonsmoker, presented with a dental history of chronic decay and periodontal disease. Her medical history included allergy to penicillin, as well as use of calcium and bupropion at the time of presentation. During the examination, the endodontic failure of tooth No. 13 was revealed, necessitating its extraction. The extraction of tooth No. 13 resulted in a large apical defect at the site, in addition to significant destruction of the labial plate (Figure 1A). Mineralized particulate bone (Puros) was placed in the defect (Figure 1B) and covered using a regenerative collagen matrix membrane (Puros Pericard-

ium^a) (Figure 1C). The particulate bone/membrane complex was sutured using Vicryl 4/0 sutures, leaving incomplete soft-tissue coverage of the membrane.^{3,23} However, 2 weeks after surgery, the absorbable membrane remained intact (Figure 1D), serving as a barrier during this critical period of wound healing. Three months after surgery, adequate areas of keratinized tissue had been achieved as a result of using the Pericardium membrane (Figure 1E). For this case, the patient ultimately received an implant and esthetic single-unit restoration and, 2 years after surgery, excellent soft-tissue contours (Figure 1F) and implant osseointegration had been realized, as seen in a 2-year postoperative radiograph (Figure 1G).

Case No. 2 (Dr. Keith): Bone Atrophy and Congenitally Missing Lateral Incisor

An 18-year-old woman presented with a chief complaint regarding the congenitally missing tooth No. 10 (Figure 2A). Her medical history was negative, she was a nonsmoker, and she had undergone prior orthodontic therapy. The patient was treatment planned to receive an implant-supported crown restoration after augmentation of the severely atrophied alveolar bone in the area of missing tooth No. 10 using an allograft bone block graft (Puros) and regenerative collagen membrane (BioMend Membrane^a).¹⁶ The allograft bone block was placed and after 5 months of healing, demonstrat-

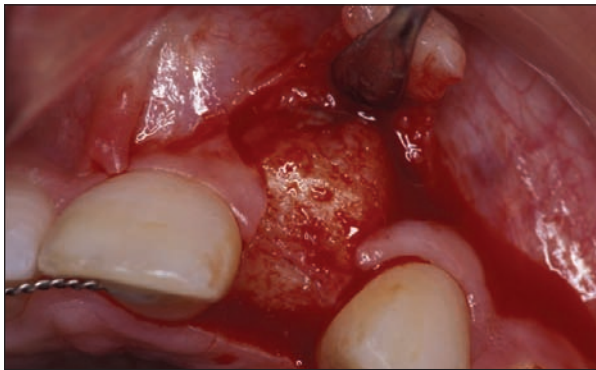

Figure 2E—View of the extensive surgical exposure of the block allograft at 5 months to remove titanium screws that were used to anchor the block.

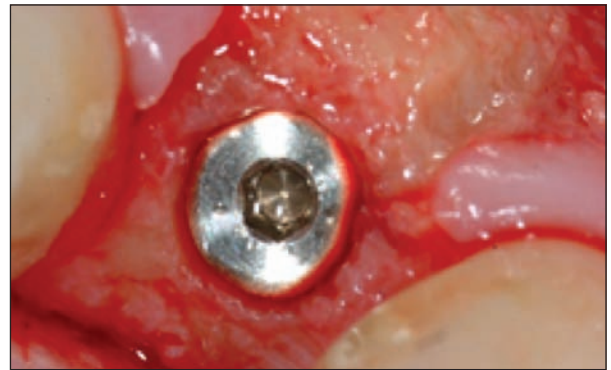


Figure 2F—A 3.3-mm Tapered Screw Vent implant was surgically placed.

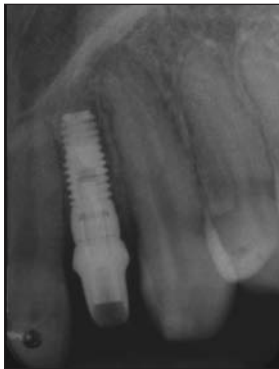

Figure 2G—Radiographic view of the No. 10 implant after surgical placement.

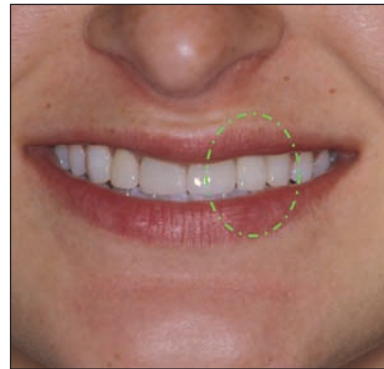
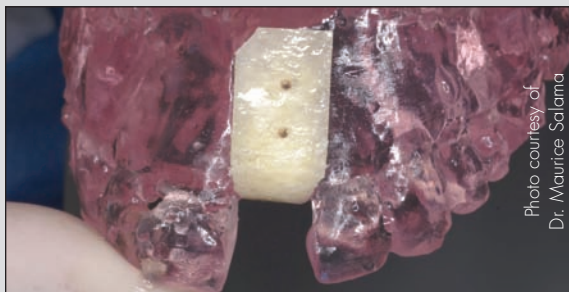
Figure 2H—View of the patient in natural smile after the placement of the definitive implant-supported crown restoration at the No. 10 site. Note the symmetry with the contralateral maxillary lateral incisor.

ed the desired cortical/trabecular patterns necessary for dimensional ridge augmentation (Figure 2B).

Alternatively, the case could have been treatment planned for ridge augmentation and implant placement using a 3-D software program, CT scan, and a stereolithic model, onto which the bone graft material would be prefitted (See Box).^{17-19,26}

Alternative Treatment Plan



The incorporation of a CT-derived, model-based surgical guide has been shown to facilitate accurate and repeatable presurgical prosthetic planning and precise implant placement.¹⁹ Additionally, the use of CT scans may remove the limitations typically associated with 2-dimensional implant imaging regimens, allowing more relevant clinical information to be translated into the treatment plan and ultimately transferred to the patient's mouth when performing the surgical protocol.^{19,20} For example, the information obtained from CT scans can promote better understanding of the anatomical relationship between the tooth (and/or implant) and the bone surrounding and/or anticipated to surround it.²⁰ In this figure, the Zimmer J-Block was shaped onto a sterilized 3D model^b generated from the CT scan (i-CAT, Imaging Sciences North America; www.imagingciences.com) before surgery, increasing the accuracy of the fit and expediting the procedure.

The preoperative panoramic radiograph identified the root positions of teeth Nos. 9 and 11, as well as their mesiodistal spatial relationship. This mesiodistal space was compared with the contralateral maxillary right lateral incisor (Figure 2C) for reference. Once placed, the bone block allograft was covered by the BioMend membrane (Figure 2D), and its placement confirmed radiographically.

At 5 months, the block allograft was surgically exposed (Figure 2E) and the titanium screws were removed. A 3.3-mm Tapered Screw Vent implant^a was surgically placed in the No. 10 site (Figure 2F), and its placement/position confirmed radiographically (Figure 2G). A provisional crown restoration was placed at this visit. Upon completion of the definitive crown restoration 3 months later, the temporary was removed and the final implant-supported crown restoration was placed (Figure 2H).

Case No. 3 (Dr. Salama): Sudden Edentulous Segment/Fixed Partial Denture Fracture

A 52-year-old woman presented after her 4-unit fixed partial denture in the maxillary left quadrant fractured off, leaving teeth Nos. 11 and 12 (ie, abutments) fractured at the gumline and hopeless (Figure 3A). As a result, the patient was now edentulous in that area. The teeth were extracted atraumatically (Figure 3B) and the sockets planned for implant placement.

Using 3-D computer software (SimPlant^b), implant placement was preplanned and a surgical guide fabricated (SurgiGuide^b) based on the predetermined appropri-

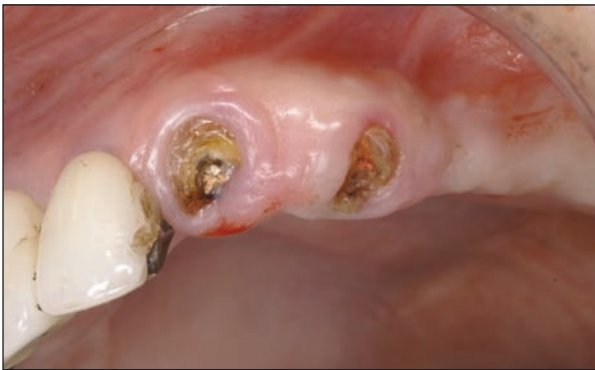

Figure 3A—Preoperative view of the patient at presentation. Teeth Nos. 11 and 12 (ie, abutments) were fractured at the gumline when the 4-unit fixed partial denture broke off and are now hopeless.

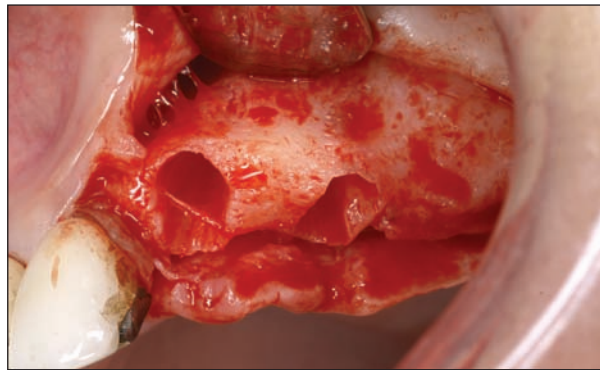


Figure 3B—View of the remaining socket environment after tooth extraction into which implants will ultimately be placed. Notice the remaining thin labial bone present.

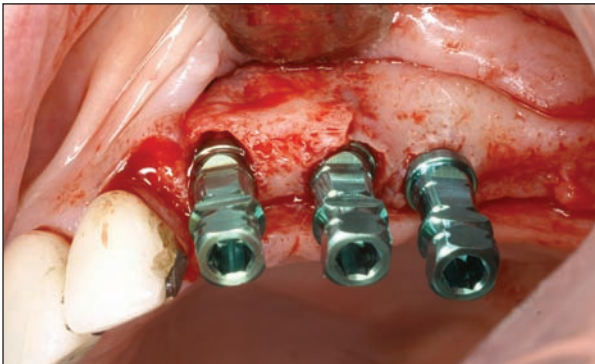


Figure 3C—Three 3.7-mm Tapered Screw Vent implants were placed into the edentulous ridge and extraction sockets at the Nos. 11, 12, and 13 sites.

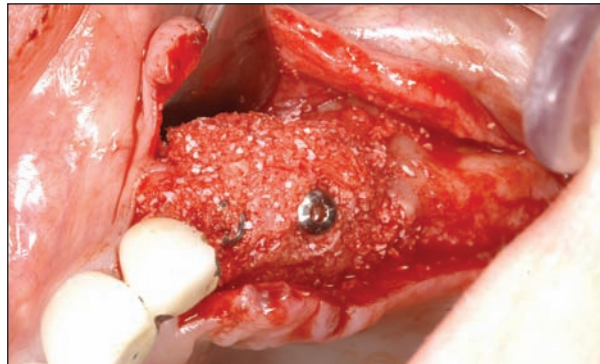


Figure 3D—To prevent further resorption of the buccal plate of bone in front of the implants, the inside and outside of the socket were grafted with a 50:50 mixture of mineralized cancellous allograft (Puros) and bovine bone (Bio-Oss) with PRGF.

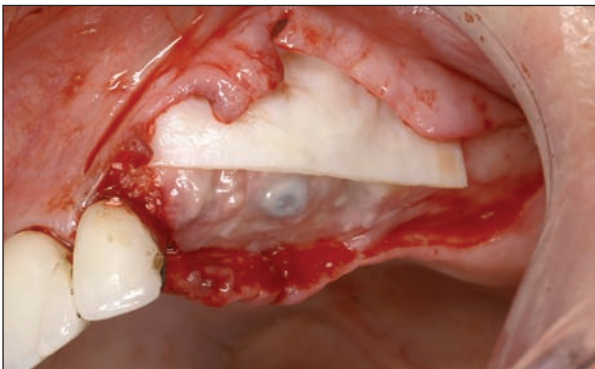


Figure 3E—The bone graft complex was covered and stabilized with a fibrin membrane over which a Pericardium allograft membrane was placed.

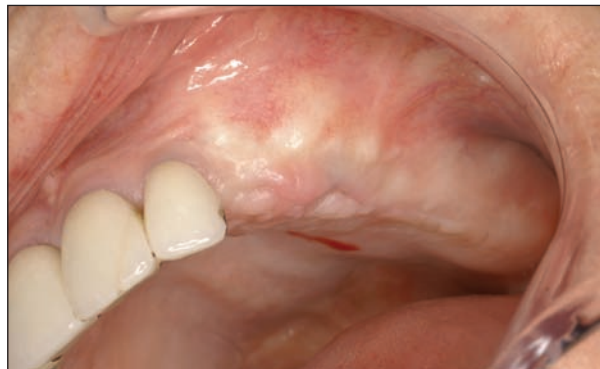

Figure 3F—At 4 months postoperative, the ridge had been successfully and significantly augmented in both the horizontal and vertical directions.

ate location for implant insertion to accommodate future restorative needs, not on the location of current bone volume. This guide was prefabricated with die-cut holes to indicate the precise location for the drill/implants during surgery, as determined by the 3-D software.

Three implants (3.7-mm Tapered Screw Vent implants^a) were placed into the edentulous ridge and extraction sockets (ie, Nos. 11, 12, and 13 sites) (Figure 3C). Healing abutments (eg, 3 mm) were placed on the implants in the areas of Nos. 11 and 12, and a cover screw was placed in the area of No. 13.

^b Materialise Dental Inc, Glen Burnie, MD; www.materialise.com

However, it can be appreciated that the buccal plate in front of these implants was very thin. To prevent further resorption of this bone, the inside and outside of the socket were grafted with a mixture of cancellous particulate bone allograft (50/50 mixture of Puros Cancellous Particulate Allograft^a and Bio-Oss^c)^{13,27-30} (Figure 3D). The cancellous bone allograft mixture was combined with a preparation rich in growth factor (PRGF).^{24,25} The bone graft complex was covered with fibrin, over which a regenerative collagen membrane (Puros Pericardium Allograft Membrane) was placed to protect the bone graft, as well as add thickness

^c Osteohealth, Shirley, NY; www.osteohhealth.com

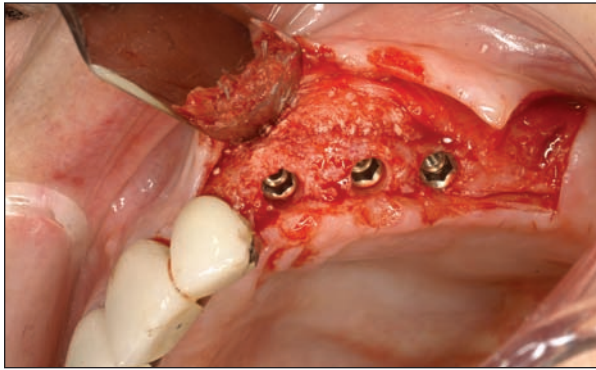


Figure 3G—At approximately 5 months postoperative, the surgical site was re-entered to expose the implants, at which time a significant increase in ridge dimensions was again observed (ie, buccal augmentation of between 4 mm and 5 mm and also vertically above the level of the fixture heads on the implants at site Nos. 11 and 12).

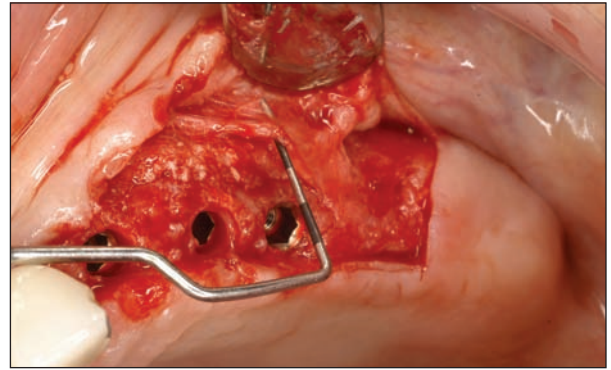


Figure 3H—Remnants of the Pericardium allograft membrane were still in place and well incorporated with the surrounding natural bone and soft tissue to protect the bone graft.

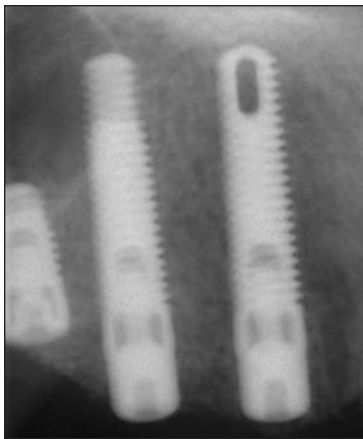


Figure 3I—The extent of bone augmentation was verified radiographically. Bone can be seen to have developed over the top of the 3-mm healing abutments at the implant site for Nos. 11 and 12, as well as over the cover screw at site No. 13.

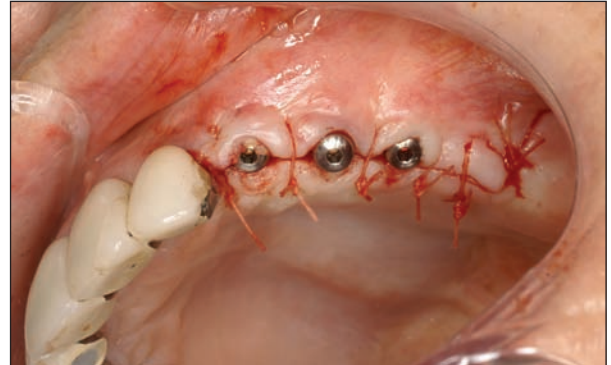


Figure 3J—To expose the implants to tissue, longer 5-mm healing abutments were placed, and the patient was scheduled for routine impression taking and delivery of the final restoration 4 weeks later.

to the tissue and ridge (Figure 3E), and a tension-free closure was achieved. Note that the autologous fibrin demonstrates an elastic consistency that functions as an ideal biomaterial membrane for sealing postextraction wounds and inducing cell proliferation.^{24,25} Four months after surgery, the ridge had been successfully and significantly augmented both horizontally and vertically (Figure 3F).

At approximately 5 months after surgery, the surgical site was re-entered to expose the implants, at which time a significant increase in ridge dimensions was again observed. Specifically, the bone had been augmented buccally (ie, horizontally) up to between 4 mm and 5 mm,

The materials and surgical techniques in use today enable clinicians to more predictably ensure the functional and esthetic outcomes of the implants and subsequent restorations that are delivered.

and also vertically above the level of the fixture heads on the implants at site Nos. 11 and 12 (Figure 3G). Additionally, remnants of the collagen membrane barrier were still in place and well incorporated with the surrounding natural bone and soft tissue to protect the bone graft (Figure 3H). This is significant because profession-

als who choose to use a collagen barrier require a material that is first accepted by the body, incorporated by the body, and not resorbed too quickly to protect the underlying graft.^{1,3,23}

The extent of bone augmentation was verified radiographically (Figure 3I). To expose the implants to tissue, longer 5-mm healing abutments were placed (Figure 3J). At the time of writing, the patient was scheduled for routine impression taking and delivery of the final restoration in about 4 weeks.

Conclusion

Myriad regenerative products (eg, bone allografts, cancellous bone, bioactive modifiers, PRGF, fibrin membranes)¹² in combination with careful treatment strategies that may, on occasion, involve 3-D imaging, CT scans, and surgical planning using stereolithic models and surgical guides, are helping to change the face of implant and restorative dentistry and contributing to more predictable long-term results. Given the propensity for the alveolar ridges to resorb after tooth extraction and/or as a result of atrophy, it behooves clinicians to understand the benefits and elements of socket and bone preservation/augmentation techniques and the materials that can be used for these purposes³¹ to enhance

the ultimate outcome of implant placement and subsequent restorative treatment.

Disclosure

Dr. Salama has been a consultant, lecturer, and/or principal investigator in clinical and laboratory studies and product evaluations sponsored through contractual relationships with the following corporations: Zimmer Dental, Nobel Biocare, Straumann, ITI Implant Innovations Inc, Lifecore, Dentsply, Friadent, Brasseler USA, Imaging Sciences, BioHorizons, 3M ESPE, Bisco, Biora, Siemens, Premier, GC America, Ivoclar Vivadent, Den-Mat, Shofu, ProDentec, Panasonic, Minolta, Kodak, Sony, Vident, Hu-Friedy, National Dental Network, Global Surgical, Materialise, Biolase, Belmont, Consult Pro, Stoma, XCPT, Titan Instruments, Heraeus Kulzer, Cosmedent, and LED Dental. Dr. Keith receives an honorarium from Zimmer Dental.

References

1. Drakos D, Engler-Hamm D. Ridge preservation: why and when. *Implants*. 2006;3:20-23.
2. Levine RA, Horowitz RA. Bone reconstructive surgery for implant site preparation. *Functional Esthetics & Restorative Dentistry*. 2007;Series 1 (No. 2): 20-28; a supplement to *Inside Dentistry*, 2007, Vol. 3 (No. 7).
3. Sonick M, Hwang D. Tooth extraction—an opportunity for site preservation. *Contemp Esthetics*. 2007 Feb;11(2):36-41.
4. Petrunaro PS, Amar S. Localized ridge augmentation with allogenic block grafts prior to implant placement: case reports and histologic evaluations. *Implant Dent*. 2005;14:139-148.
5. Iasella JM, Greenwell H, Miller RL, et al. Ridge preservation with freeze-dried bone allograft and a collagen membrane compared to extraction alone for implant site development: a clinical and histologic study in humans. *J Periodontol*. 2003;74:990-999.
6. Nevins M, Camelo M, De Paoli S, et al. A study of the fate of the buccal wall of extraction sockets of teeth with prominent roots. *Int J Periodontics Restorative Dent*. 2006;26:19-29.
7. Schropp L, Wenzel A, Kostopoulos L, et al. Bone healing and soft tissue contour changes following single-tooth extraction: a clinical and radiographic 12-month prospective study. *Int J Periodontics Restorative Dent*. 2003;23:313-323.
8. Lekovic V, Camargo PM, Klokkevold PR, et al. Preservation of alveolar bone in extraction sockets using bioabsorbable membranes. *J Periodontol*. 1998;69:1044-1049.
9. Lekovic V, Kenney EB, Weinlaender M, et al. A bone regenerative approach to alveolar ridge maintenance following tooth extraction. Report of 10 cases. *J Periodontol*. 1997;68:563-570.
10. Spray JR, Black CG, Morris HF, et al. The influence of bone thickness on facial marginal bone response: stage 1 placement through stage 2 uncovering. *Ann Periodontol*. 2000;5:119-128.
11. Buser D, Martin W, Belsler UC. Optimizing esthetics for implant restorations in the anterior maxilla: anatomic and surgical considerations. *Int J Oral Maxillofac Implants*. 2004;19 (Suppl):43-61.
12. Wang HL, Cooke J. Periodontal regeneration techniques for treatment of periodontal diseases. *Dent Clin North Am*. 2005; 49:637-659, vii.
13. Block MS, Degen M. Horizontal ridge augmentation using human mineralized particulate bone: preliminary results. *J Oral Maxillofac Surg*. 2004;62 (9 Suppl 2):67-72.
14. Minichetti JC, D'Amore JC, Hong AY, et al. Human histologic analysis of mineralized bone allograft (Puros) placement before implant surgery. *J Oral Implantol*. 2004;30:74-82.
15. Nounbissi SS, Lozada JL, Boyne PJ, et al. Clinical, histologic, and histomorphometric evaluation of mineralized solvent-dehydrated bone allograft (Puros) in human maxillary sinus grafts. *J Oral Implantol*. 2005;31:171-179.
16. Keith JD Jr, Petrunaro P, Leonetti JA, et al. Clinical and histologic evaluation of a mineralized block allograft: results from the developmental period (2001-2004). *Int J Periodontics Restorative Dent*. 2006;26:321-327.
17. Leonetti JA, Koup R. Localized maxillary ridge augmentation with a block allograft for dental implant placement: case reports. *Implant Dent*. 2003;12:217-226.
18. Jacotti M. Simplified onlay grafting with a 3-dimensional block technique: a technical note. *Int J Oral Maxillofac Implants*. 2006;21:635-639.
19. Gantz SD. CT-derived model-based surgery for immediate loading of maxillary anterior implants. *Pract Proced Aesthet Dent*. 2007;19:311-318.
20. Gantz SD. The reality of anatomy and the triangle of bone. *Inside Dentistry*. 2006;2:72-77.
21. Buser D, Dula K, Lang NP, et al. Long-term stability of osseointegrated implants in bone regenerated with the membrane technique. 5-year results of a prospective study with 12 implants. *Clin Oral Implants Res*. 1996;7:175-183.
22. Nevins M, Mellonig JT, Clem DS 3rd, et al. Implants in regenerated bone: long-term survival. *Int J Periodontics Restorative Dent*. 1998;18:34-45.
23. Friedmann A, Strietzel FP, Marezki B, et al. Histological assessment of augmented jaw bone utilizing a new collagen barrier membrane compared to a standard barrier membrane to protect a granular bone substitute material. *Clin Oral Implants Res*. 2002; 13:587-594.
24. Anitua E, Orive G, Andia I. Use of PRGF to accelerate bone and soft tissue regeneration in postextraction sites. *Implant Dialogue*. 3-14.
25. Anitua E, Andia I, Sanchez M, et al. Autologous preparations rich in growth factors promote proliferation and induce VEGF and HGF production by human tendon cells in culture. *J Orthop Res*. 2005;23:281-286.
26. Keith JD. Localized ridge augmentation with a block allograft followed by secondary implant placement: a case report. *Int J Periodontics Restorative Dent*. 2004;24:11-17.
27. Froum SJ, Wallace SS, Elian N, et al. Comparison of mineralized cancellous bone allograft (Puros) and anorganic bovine bone matrix (Bio-Oss) for sinus augmentation: histomorphometry at 26 to 32 weeks after grafting. *Int J Periodontics Restorative Dent*. 2006;26:543-551.
28. Zitzmann NU, Scharer P, Marinello CP, et al. Alveolar ridge augmentation with Bio-Oss: a histologic study in humans. *Int J Periodontics Restorative Dent*. 2001;21:288-295.
29. Artzi Z. Coronal ridge augmentation in the absence of bilateral bony plates around a pathologically denuded implant surface. *Int J Periodontics Restorative Dent*. 2000;20:191-197.
30. Maiorana C, Santoro F. Maxillary and mandibular bone reconstruction with hip grafts and implants using Frialit-2 implants. *Int J Periodontics Restorative Dent*. 2002;22:221-229.
31. Alam A-A, Nowzari H. Mandibular cortical bone grafts part 1: anatomy, healing process, and influencing factors. *Compend Contin Educ Dent*. 2007;28:206-213.

Quiz 3

- Bone volume in the alveolar ridges influences which of the following?**
 - esthetics of definitive restorations
 - success or failure of implants
 - location/position of implants
 - all of the above
- Alveolar bone loss can occur after:**
 - extraction only.
 - trauma only.
 - extraction or trauma.
 - orthodontic treatment.
- What may occur when the alveolar bone resorbs horizontally and vertically?**
 - A lingually positioned ridge may result.
 - Bone volume may increase by 3.0 mm horizontally.
 - Bone volume may increase by 2.0 mm vertically.
 - No additional changes occur.
- If the alveolar ridge is not preserved at the time of tooth extraction or tooth loss, alveolar ridge height and width may be lost, particularly:**
 - in the area of the buccal plate.
 - along the maxillary ridge.
 - along the mandibular ridge.
 - along the midline.
- In the first year after extraction, which of the following has been reported?**
 - bone loss between 1 mm and 2 mm horizontally
 - bone loss between 3 mm and 6 mm horizontally
 - bone loss between 2 mm and 3 mm vertically
 - bone loss between 3 mm and 6 mm vertically
- Which of the following is *not* required for implant placement?**
 - sufficient bone height
 - sufficient bone width
 - maximum bone on the buccal and lingual aspects of 1 mm
 - at least 2 mm of facial bone in the esthetic area
- Which of the following is the most predictable way to maintain width, height, and position of the alveolar ridge?**
 - ridge preservation at the time of tooth extraction
 - bone regeneration with barrier membranes
 - bone regeneration with bone grafts
 - bone regeneration with biologic modifiers
- Which category of bone graft materials contains human bone?**
 - autografts and allografts
 - allografts and alloplasts
 - alloplasts and autografts
 - xenografts and alloplasts
- Xenografts and alloplasts:**
 - are osteoinductive.
 - are osteoconductive.
 - can be demineralized freeze-dried bone.
 - can be mineralized freeze-dried bone.
- Because mineralized freeze-dried bone allografts contain calcium and phosphate salts they:**
 - resorb slower than demineralized freeze-dried allografts.
 - resorb faster than demineralized freeze-dried allografts.
 - resorb faster than xenografts.
 - resorb faster than alloplasts.

-
11. Which of the following is *not* part of the requisite technique for placing a sterilized, mineralized block allograft?
- proper contouring and shaping of the block
 - screw fixation to prevent rotation
 - tight soft-tissue closure with visible tension
 - coverage of the graft site with a barrier membrane
12. When placed in atrophic human maxillae, one mineralized bone allograft has been shown to:
- form new bone.
 - achieve osseointegration of all placed tapered screw-vent implants.
 - provide rapid resorption and replacement by new bone.
 - all of the above
13. Cortico-cancellous bone allograft can eliminate which of the following?
- precise shaping and contouring to adapt the allografts to the defect site
 - use of imaging and modeling technology
 - surgery necessary for harvesting an autograft
 - preparation and placement of block allografts
14. Using 3-D CT scanning eliminates which of the following?
- bleeding
 - flaps
 - restricted access
 - all of the above
15. Using CT scans in the preparation of block allografts:
- adds time and stress to the procedure.
 - limits the clinicians ability to critique the allograft before placement.
 - reduces the risk of complications or failures from poorly contoured allografts.
 - may result in increased failures.
16. One study showed that bone regenerated using a membrane technique reacts to implant placement like:
- nonregenerated bone.
 - cortico-cancellous bone allograft.
 - xenografts.
 - allogenic bone.
17. Barrier membranes may be:
- resorbable.
 - nonresorbable.
 - acellular dermal matrices.
 - all of the above
18. Which of the following is a resorbable barrier membrane?
- collagen
 - expanded polytetrafluoroethylene
 - PRGF
 - cortico-cancellous bone
19. Biologic modifiers include preparations rich in growth factors harvested from?
- the patient's own blood
 - animal bone
 - human bone not from the patient
 - synthetic materials
20. Biologic modifiers and barrier membranes or a combination thereof have demonstrated clinical efficacy for:
- site preparation.
 - augmentation.
 - implant integration.
 - all of the above

Please see tester form on page 624.

This article provides 2 hours of CE credit from Ascend Dental Media, in association with the University of Southern California School of Dentistry and the University of Pennsylvania School of Dental Medicine, representatives of which have reviewed the articles in this issue for acceptance. Record your answers on the enclosed answer sheet or submit them on a separate sheet of paper. You may also phone your answers in to (888) 596-4605 or fax them to (703) 404-1801. Be sure to include your name, address, telephone number, and last 4 digits of your Social Security number.

